

# VALIDATION OF A FEMORAL RESURFACING ALIGNMENT DEVICE USING COMPUTER AIDED NAVIGATION

Ashish Phadnis\*, Keshav Singhal\*, Ville Pitkänen@, Andy Turner@

\* Princess Of Wales Hospital, Bridgend, South Wales, UK  
 @ Biomet UK Ltd, Bridgend, South Wales, UK

Investigation performed at Department of Anatomy MGM Medical College and D.Y.Patil Medical College in Navi Mumbai, India.

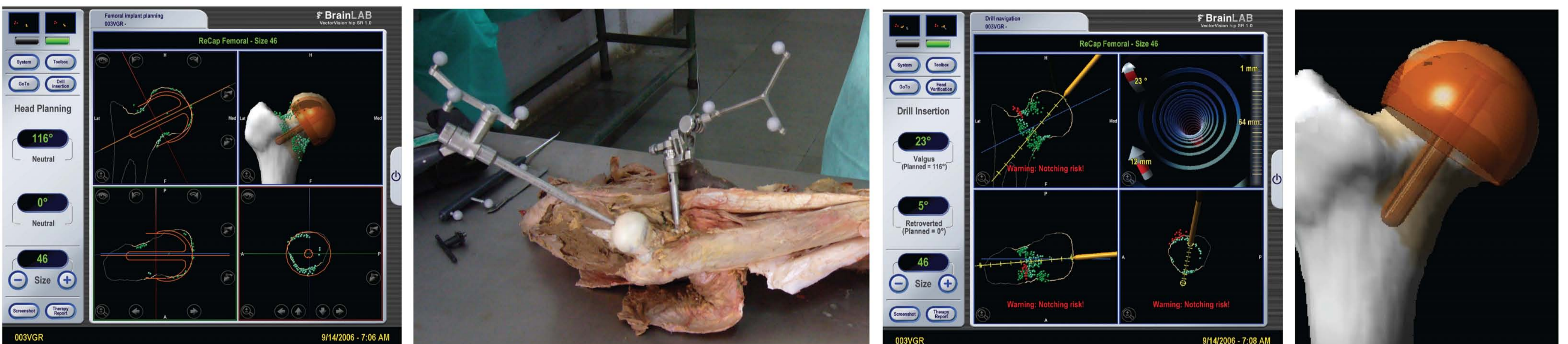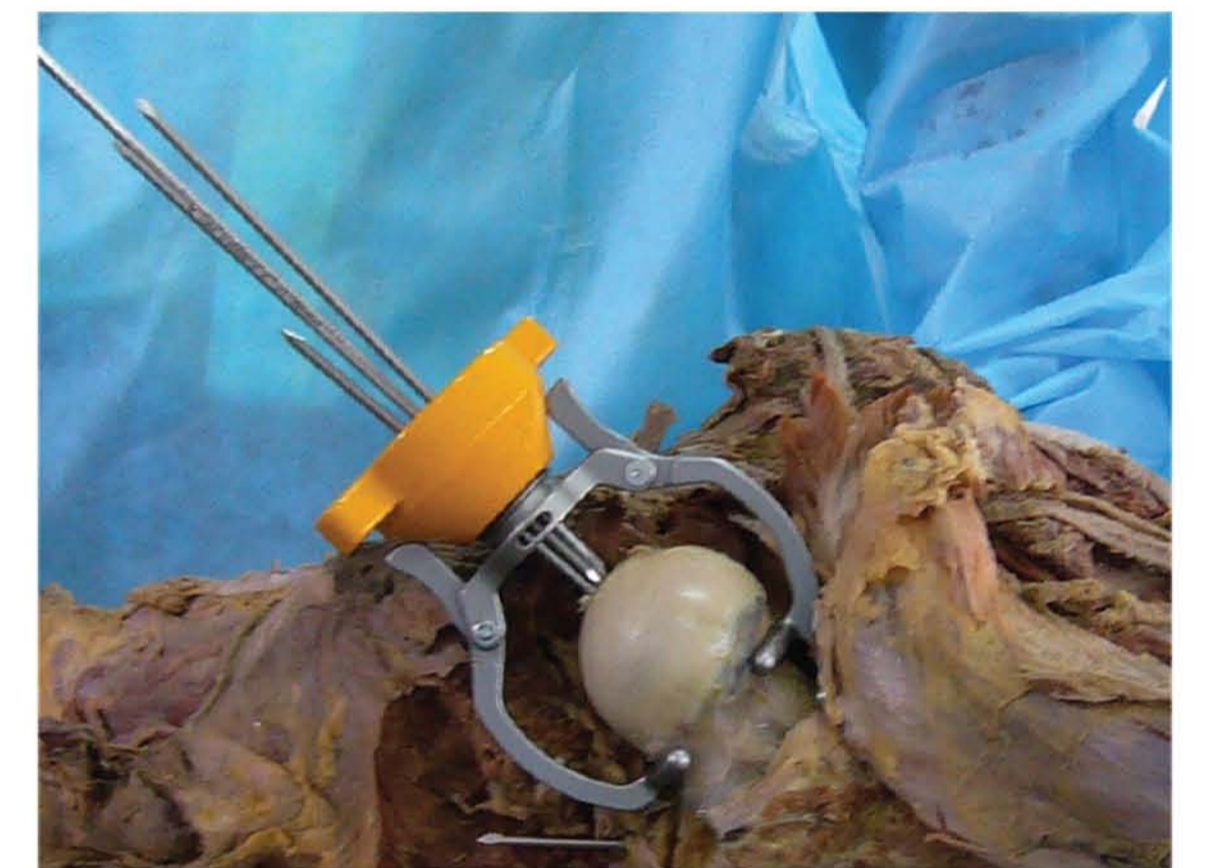
## PURPOSE OF STUDY

- Validate Alignment Device in cadaveric femoral using Computer Aided Navigation
- Assess the reliability and reproducibility of the Alignment Device using Computer Aided Navigation

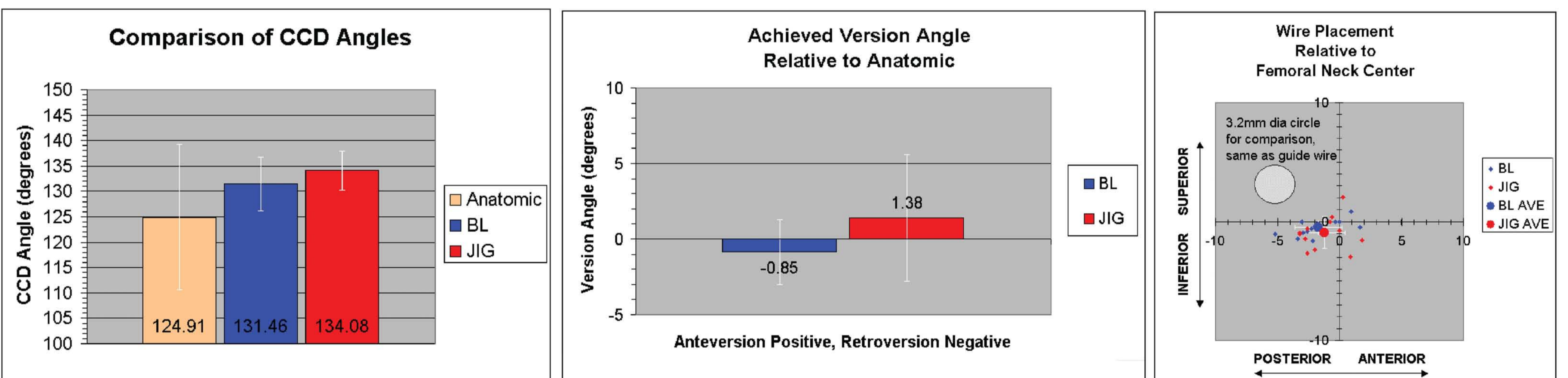


## MATERIALS AND METHODS

- Study conducted with 13 cadaveric femurs
- All 13 femurs were calibrated using Computer Aided Navigation
- The femoral components were templated to all 13 femurs using both the Alignment Device and Computer Aided Navigation
- Results were compared based on data from the Navigation System



## RESULTS



## CONCLUSION

- The Alignment Device consistently placed the implant within acceptable limits to the position determined by Computer Aided Navigation templating

# FEMORAL RESURFACING COMPONENT POSITION USING AN ALIGNMENT DEVICE VERSUS COMPUTER AIDED NAVIGATION

Ashish Phadnis\*, Keshav Singhal\*, Ville Pitkänen@, Andy Turner@

\* Princess Of Wales Hospital, Bridgend, South Wales, UK  
 @ Biomet UK Ltd, Bridgend, South Wales, UK

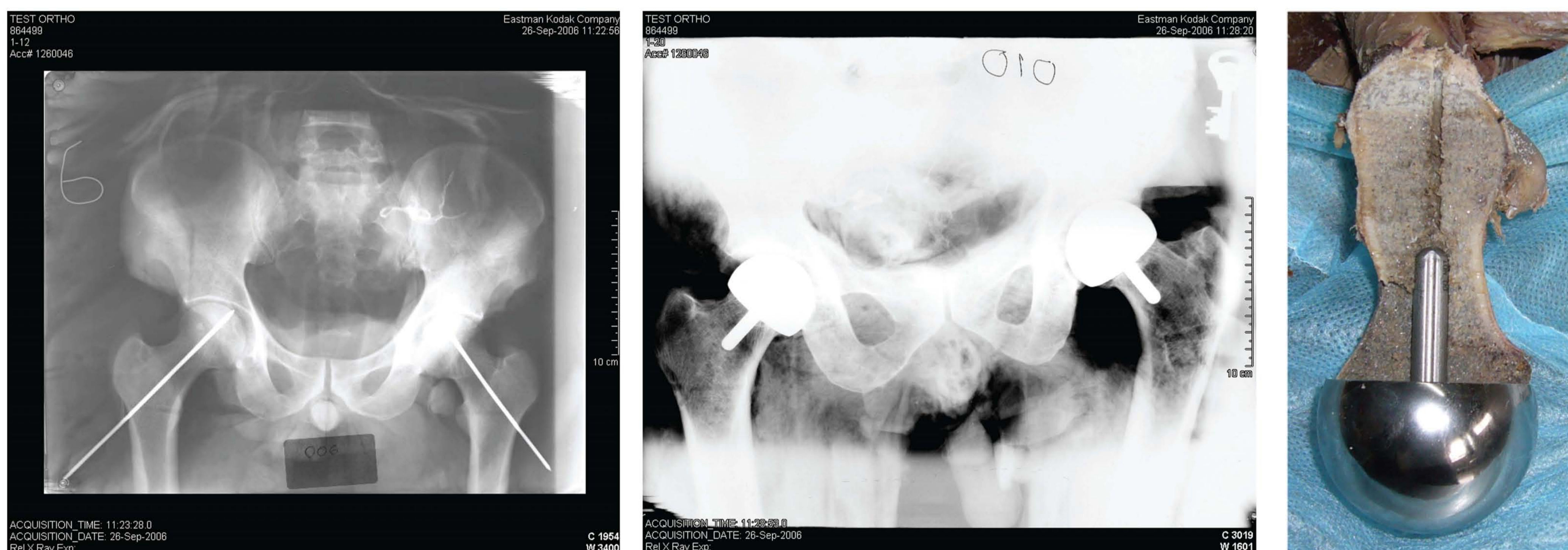Investigation performed at Department of Anatomy MGM Medical College and D.Y.Patil Medical College in Navi Mumbai, India.

## PURPOSE OF STUDY

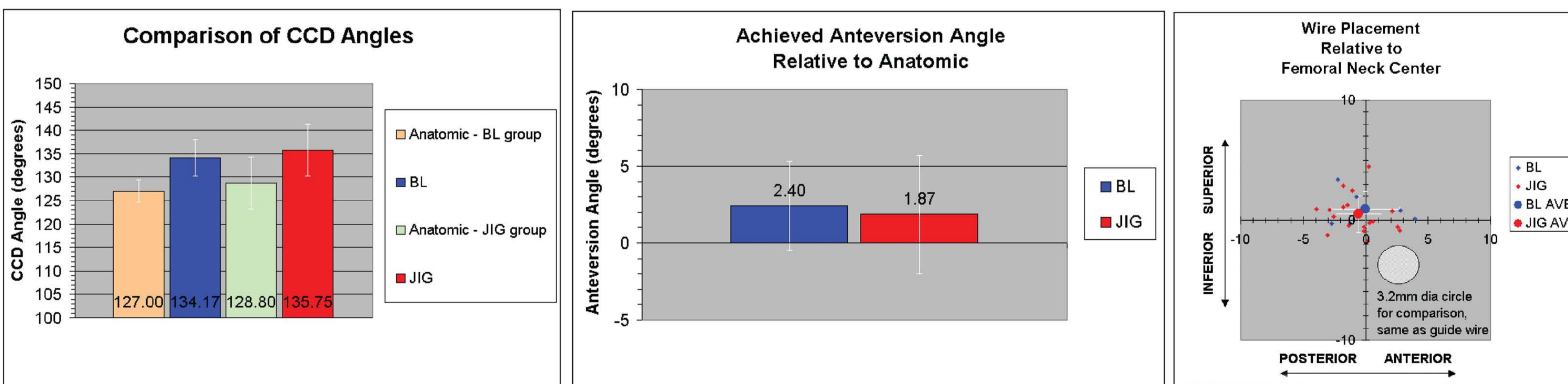
- Validate Alignment Device in cadaveric femora
- Compare the position of the Femoral Resurfacing Component as positioned by the Alignment Device versus the Computer Aided Navigation

## MATERIALS AND METHODS

- Study conducted with 26 cadaveric femurs
- Resurfacing Performed with Alignment Device by an inexperienced surgeon in 20 femurs
- Resurfacing Performed with Navigation by an experienced surgeon in 6 femurs
- Results analysed based on pre-op and post-op radiographs and cross-sections of femurs



## RESULTS



## CONCLUSION

- No significant difference in implant position between experienced surgeon using navigation and inexperienced surgeon using the alignment device

